

Current approach to bone augmentation with allogeneic cortical graft: A case report

Utku Nezir Yılmaz¹, Fatma Eriş Derkuş¹

¹ Dicle University, Faculty of Dentistry, Department of Oral and Maxillofacial Surgery, Diyarbakır, Turkey

Abstract

Aim: Today, dental implant applications have become the most preferred option in the treatment of tooth deficiencies. Long-term successful results in dental implant applications depend largely on the volume and quality of the hard and soft tissues in the relevant region. Insufficient soft tissues and alveolar crest resorption complicate implant applications. Grafts and additional surgical procedures are required to compensate for resorption and to provide bone augmentation. Shell technique, one of the augmentation methods used in the treatment of alveolar bone defects, is an important procedure for guided bone regeneration. The purpose of this case report is to describe the treatment of vertical and horizontal bone loss with the Shell technique using allogeneic cortical grafts.

Methodology: A 58-year-old female patient without any systemic disease was admitted to our clinic with the complaint of tooth loss in the right posterior mandibular region. In the intraoral and radiological examinations, it was determined that the bone volume in the relevant region was not sufficient for dental implant. Two-stage surgical treatment was planned for the patient. First, vertical and horizontal bone defects were augmented with allogeneic cortical graft application under local anesthesia. After the healing process, dental implants were placed in the sufficient volume of the alveolar bone and the patient's treatment was completed.

Conclusion: Allogeneic grafts in the treatment of alveolar crest defects; it is a good alternative to autogenous bone grafts, there is no need for a second surgical field and the resulting reduction in morbidity.

Keywords: allogeneic bone graft, allogeneic cortical strut, biomaterials, augmentation, shell technique

How to cite this article: Yılmaz UN, Eriş Derkuş F. Current approach to bone augmentation with allogeneic cortical graft: A case report. *Int Dent Res* 2021;11(Suppl.1):299-302. <https://doi.org/10.5577/intdentres.2021.vol11.suppl1.44>

Correspondence:

Dr. Fatma ERIŞ DERKUŞ
Dicle University, Faculty of Dentistry,
Department of Oral and Maxillofacial
Surgery, Diyarbakır, Turkey.
E-mail:erisfatma92@gmail.com

Received: 15 March 2021

Accepted: 11 May 2021

Access Online



DOI:

10.5577/intdentres.2021.vol11.suppl1.44

Introduction

The posterior mandible is a region where early tooth loss is common due to periodontal, endodontic or developmental diseases (1). Dental implant applications are becoming more common every day in the treatment of tooth deficiencies. Successful results in rehabilitation with dental implants depend on the adequate volume and quality of hard and soft tissues (2). Severe periodontitis, prolonged edentulism,

neoplasms or malformations may complicate implant applications by causing atrophy in the alveolar crest (3). Dental implants that are applied without treatment of bone loss can cause non-aesthetic results, and dental implants are often impossible to apply in advanced bone resorption. Therefore, in cases of volumetric insufficiency in the alveolar bone, grafts and advanced surgical treatment techniques are needed (4, 5). "Shell Technique" defined by Khoury in 2004 has become a common and important technique for directed bone

regeneration by providing vertical and horizontal bone augmentation (6). Shell Technique is based on the principle of fixing thin autologous cortical bone layers in the desired position with screws and filling them with particle grafts (7). Materials used in graft applications according to their immunological origin; It is classified as autogenous, isogenic, allogeneic and xenogenic (8). Autogenous bone grafts have been widely accepted as the gold standard due to their osteogenic, osteoconductive and osteoinductive properties (9, 10). However, the possibility of collecting autogenous grafts in limited amounts, requiring a second operation area and resulting morbidities such as pain, edema, infection, scar, paraesthesia, loss of muscle tone are important disadvantages (11, 12). Considering these limitations and complications, allogeneic grafts are an ideal alternative, especially in severe atrophies. Allogeneic grafts have been preferred in recent years due to their osteoconductive properties similar to autografts and their excellent clinical and histological results (13, 14). In this case report, Shell Technique was applied to the patient with horizontal and vertical bone loss using allogeneic cortical bone graft and the patient's demand for less invasive surgical procedure was met and the toothless area was rehabilitated with dental implant application.

Case Report

A 58-year-old female patient without any systemic disease was admitted to Dicle University, Faculty of Dentistry Oral and Maxillofacial Surgery outpatient clinic with a complaint of edentulism in the right posterior mandibular region. In the intraoral examination, it was observed that the teeth numbered 36, 46 and 47 of the patient were missing and the alveolar crest of the right mandible was thin in the form of a knife-edge (Fig. 1). Radiological examination revealed vertical and horizontal bone loss in the right mandibular alveolar crest (Fig. 2, 3). While planning a dental implant application for the treatment of tooth deficiency in the relevant area, it was decided to compensate for the missing tooth in the left mandibular area with a crown-bridge prosthesis upon the request of the patient. Bone augmentation was planned in order to treat the vertical and horizontal bone loss of the alveolar crest where dental implants will be applied and to make it ready for implant application. The patient was operated under local anesthesia. Following the nerve alveolaris inferior block and buccal infiltrative anesthesia, the mucoperiosteal flap was removed with a relaxing vertical incision in the relevant area and an incision made along the top of the alveolar crest (Fig. 4). It was made ready for graft placement by decortication on the crest. An allogeneic cortical strut of 25x10x1 mm was used. Graft immobilization was achieved with microscrew fixation. Based on the Shell technique, the cortical layers were filled with particle grafts (Fig. 5).

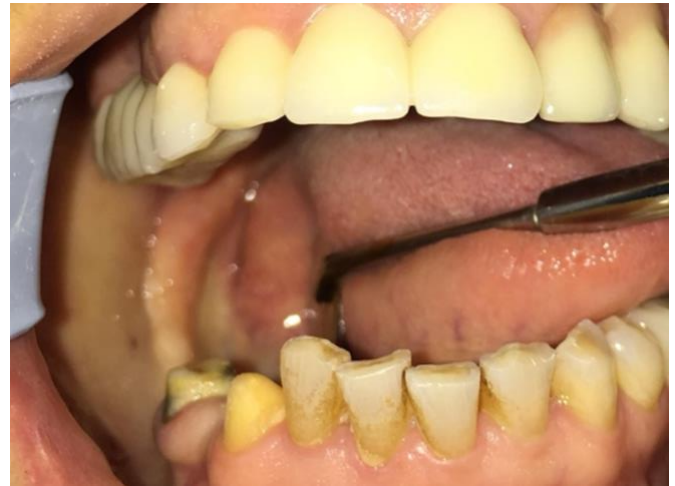

Figure 1. Intraoral view of the patient

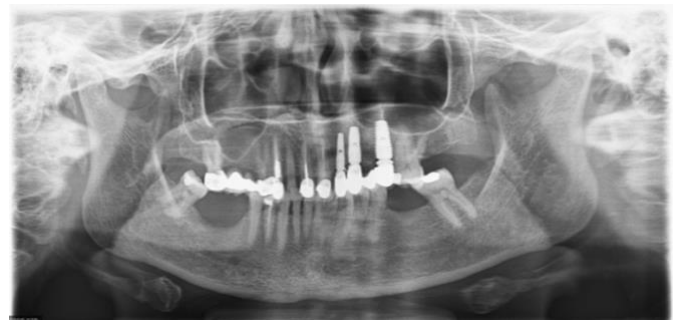

Figure 2. Preoperative panoramic radiography

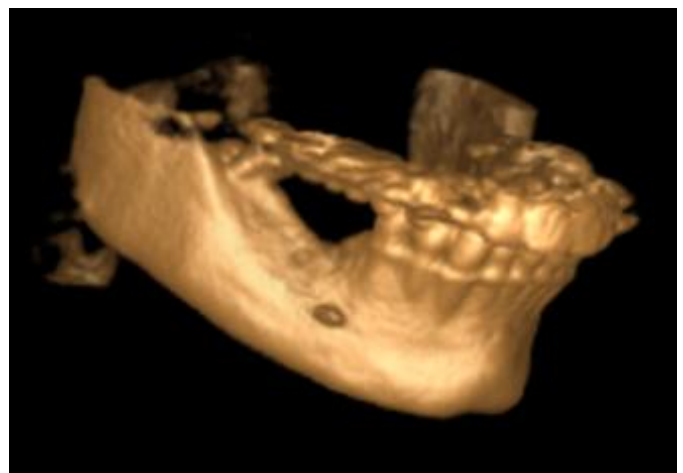


Figure 3. Preoperative cone beam computed tomography image of the patient

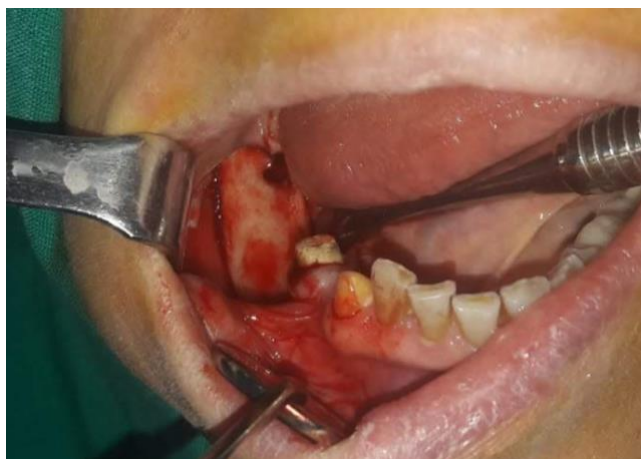

Figure 4. Intraoperative bone defect image

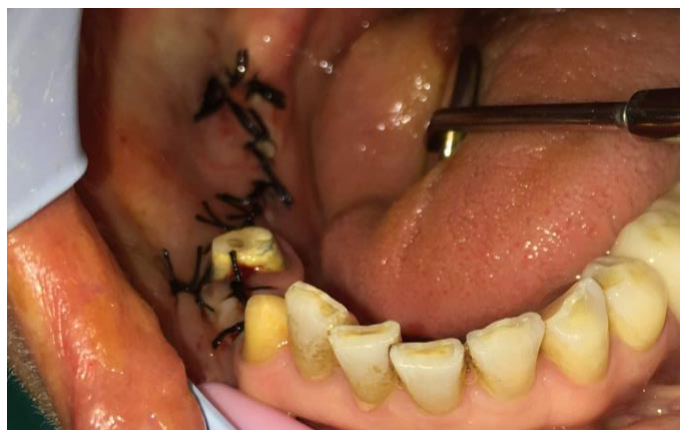

Figure 6a. Postoperative intraoral view of the patient

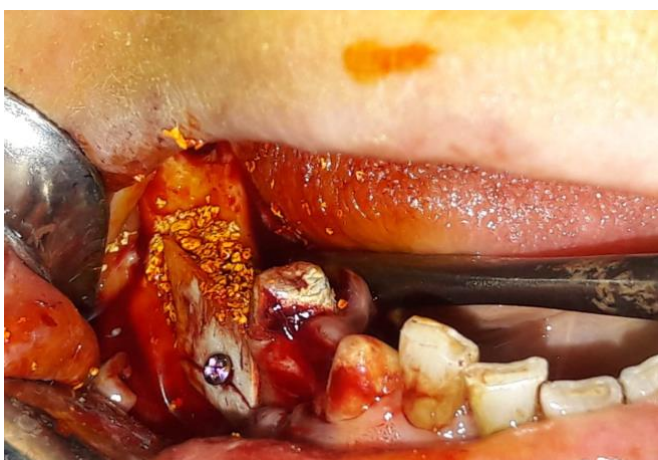

Figure 5. Application of allogeneic cortical block graft and particle grafts

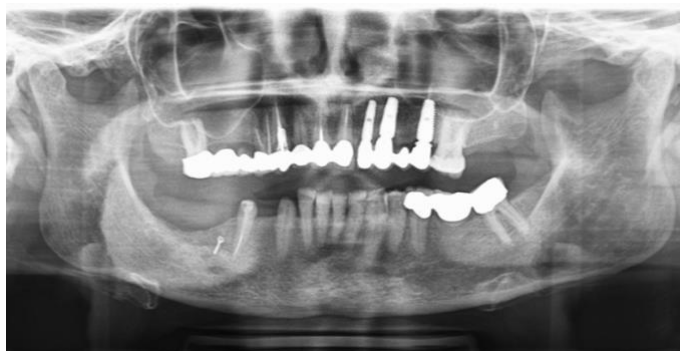

Figure 6b. Postoperative panoramic view

Sharp edges and corners were corrected to prevent flap perforation. In order to provide tension-free closure of the wound margins, incisions were made to release the periosteum. The defect area was covered with a pericardial membrane in order to preserve the volume of allogeneic bone granules during the healing process and to prevent soft tissue growth in the relevant area. The pericardium membrane was sutured in the periosteum using 5.0 vicril suture. Finally, the flap was sutured with 3.0 silk in a position where the wound margins came together without tension (Fig. 6a, 6b). After about 5 months of healing, an incision was made in the relevant area to perform dental implant application. It was observed that the allogeneic cortical strut was well integrated into the newly formed bone tissue (Fig. 7).

Two dental implants were applied and waited for osteointegration (Fig. 8a, 8b). After the 3-month healing process, healing caps were placed in order to shape the gums and ten days later, the prosthesis phase was started.

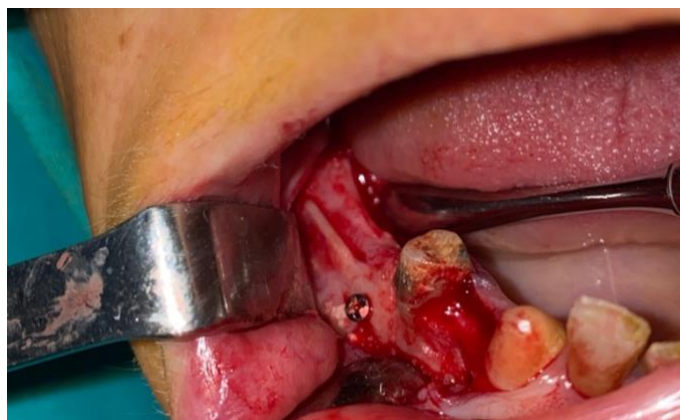

Figure 7. Bone image five months after augmentation

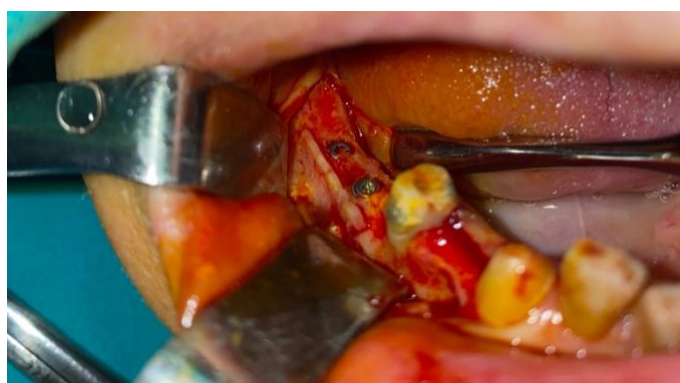

Figure 8a. Application of dental implants

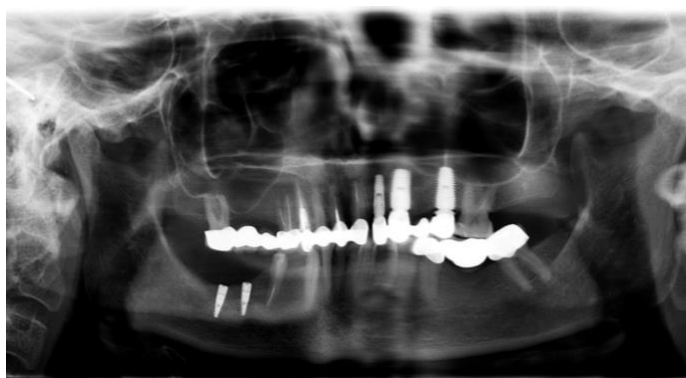


Figure 8b. Panoramic radiography after dental implant application

Conclusions

Bone defects involving more than one tooth area are difficult to treat and require invasive procedures such as intraoral or extraoral bone removal. This means a second surgical area, an increase in morbidity and an additional procedure for the patient. In such cases, the applicability of current alternative biomaterials and good clinical results provide an alternative to treatment methods that can be avoided from autogenous grafts, which are seen as gold standards. As a result, we saw in our case that allogenic cortical struts are an ideal alternative to autogenous bone transplantation. In addition, more controlled studies are needed to reach definitive conclusions about the long-term clinical performance of allogeneic cortical struts.

Acknowledgments: This study was presented as a full-text oral presentation at the 1st International Dental Research and Health Sciences Congress held between 20-22 May 2021.

Patient Consent for Publication: Written informed consent was obtained from the patient.

Peer-review: Externally peer-reviewed.

Author Contributions: Conception - U.N.Y., F.E.D.; Design - U.N.Y.; Supervision - F.E.D.; Materials - F.E.D., U.N.Y.; Data Collection and/or Processing - F.E.D.; Analysis and/or Interpretation - U.N.Y.; Literature Review - F.E.D.; Writer - U.N.Y.; Critical Review - F.E.D.

Conflict of Interest: No conflict of interest was declared by the authors

Financial Disclosure: The authors declared that this study has received no financial support.

References

1. Jacotti M, Bernardello F. Allogeneic Block Grafts in the Posterior Mandible. *Bone Augmentation by Anatomical Region*, 2020; 445-452. ([Crossref](#))
2. Ersu B. Implant Diş Hekimliğinde Kullanılan Ağiz İçi Otojen Kemik Greftleri. *Cum Uni Diş Hek Dergisi* 2007; 10: 135-140.
3. Bernstein S, Cooke J, Fotek P, Wang HL. Vertical Bone Augmentation: Where Are We Now? *Implant Dent* 2006; 15: 219-228. ([Crossref](#))
4. Misch CE, Dietsch F. Bone-grafting materials in implant dentistry. *Implant Dent* 1993; 2: 158-67. ([Crossref](#))
5. Marx RE. Clinical application of bone biology to mandibular and maxillary reconstruction. *Clin Plast Surg* 1994; 21: 377-92. ([Crossref](#))
6. Khoury F, Ponte A. The three-dimensional reconstruction of the alveolar crest with mandibular bone block graft: a clinical study. *Int J Oral Maxillofac Implants*. 2004;19:795-766.
7. Khoury F, Khoury C. Mandibular Bone Block Grafts: Diagnosis, instrumentation, harvesting techniques and surgical procedures. A. H. Khoury F içinde, *Bone augmentation in oral implantology* 2007; 115- 207. New Malden: Quintessence.
8. Kruger GO. *Text Book of Oral and Maksillofacial Surgery*. St. Louis: The CV Mosby; 1984.
9. Misch CM, Misch CE, Resnik RR, and Ismail YH. Reconstruction of maxillary alveolar defects with mandibular symphysis grafts for dental implants: A preliminary procedural report. *Int J Oral Maxillofac Implants* 1992; 7:360-366.
10. De Santis D, Trevisiol L, D'Agostino A. et al. Guided bone regeneration with autogenous block grafts applied to Le Fort I osteotomy for treatment of severely resorbed maxillae: A 4- to 6-year prospective study. *Clin Oral Implants Res* 2012; 23: 60-69. ([Crossref](#))
11. Misch CM. Comparison of intraoral donor sites for onlay grafting prior to implant placement. *Int J Oral Maxillofac Implants* 1997; 12: 767-776.
12. Misch CM. Use of the mandibular ramus as a donor site for onlay bone grafting. *J Oral Implantol* 2000; 26: 42-49. ([Crossref](#))
13. Keith JD, Jr Petrunaro P, Leonetti JA. et al. Clinical and histologic evaluation of a mineralized block allograft: Results from the developmental period (2001- 2004). *Int J Periodontics Restorative Dent* 2006; 26:321-327.
14. Jacotti M, Wang HL, Fu JH. et al. Ridge augmentation with mineralized block allografts: Clinical and histological evaluation of 8 cases treated with the 3-dimensional block technique. *Implant Dent* 2012; 21: 444-448. ([Crossref](#))